

# GASTRIC OUTLET OBSTRUCTION IN A PHYSICALLY ACTIVE, YOUNG WOMAN

## Introduction

Gastric myoelectrical activity recorded during an Electrogastrogram (EGG) test can reveal distinctive patterns in patients with gastroparesis due to mechanical obstruction compared to those with idiopathic gastroparesis.<sup>(1)</sup> EGGs are recorded non-invasively through cutaneous electrodes placed on the patient's upper abdomen. In humans, the normal frequency is 3 cycles per minute (cpm).<sup>(2)</sup> Bradygastria is an abnormally slow frequency (1.0-2.5 cpm), while tachygastria is an abnormally rapid frequency (3.75-10.0 cpm). This test is typically recorded for 15 minutes in the fasting state and then for 30 minutes after an appropriate test meal or water load.\* Water load is often preferred because comparable results can be achieved in less time (30 minutes versus 2 hours) and the effects of secretin, cholecystokinin and other hormonal responses are limited due to the lack of calories in the test meal. Water load also avoids stimulating colonic neuromuscular activity, while still provoking symptoms such as bloating and nausea.

The utility of EGG as an aid in diagnosing and treating a gastric outlet obstruction is demonstrated in the following case.

\* 3CPM proprietary EGGSAS® software compares patient results with control values that were established using a water load as the test meal.

## Patient History

A 35-year old female, thin body habitus, physically active. Presenting symptoms included postprandial bloating, abdominal distention, and early satiety, progressive over 1-2 years, as well as retrosternal burning.

## Evaluation Procedures

Esophagogastroduodenoscopy (EGD) showed patent but mildly stenotic pyloric sphincter. Nuclear solid-phase gastric emptying time (GET) scan showed a 50% emptying time of 115 minutes, which was mildly prolonged (in this practice region normal is 50% emptied in 90 minutes). All blood work was normal, including electrolytes and thyroid studies.

## 3CPM™ Electrogastrogram Analyzer Results

The EGG and water load test showed an abnormally elevated 3 cpm signal, which increased in response to water load test. The total water load tolerated by the patient was 450 ml (normal is ~ 600 ml).

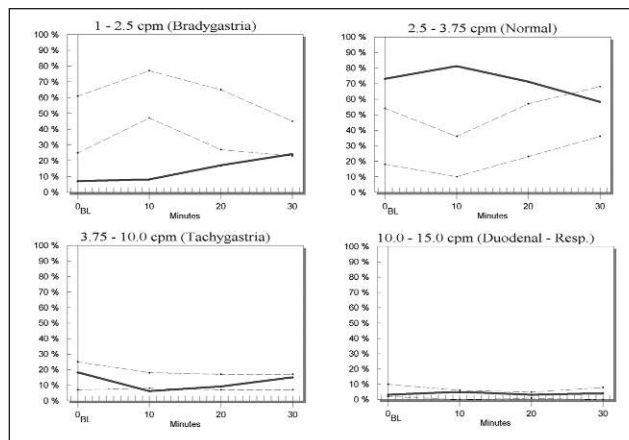



Figure 1. EGG Summary Report Pre-intervention. Patient demonstrates elevated 3 cpm that does not improve with water load.



**Mark D. Noar, MD**  
 Director & CEO  
 Endoscopic Microsurgery Associates, PA  
 Therapeutic Endoscopy &  
 Gastroenterology  
 Baltimore, MD

**Director & CEO**  
 The Endoscopy Center at Towson, Inc.  
 The Endoscopy Center at Bel Air, LLC  
 Towson, MD  
 Maryland Gastroenterology  
 Network, Inc. Baltimore, MD

**Board of Directors & Legislative Chair**  
 Maryland Ambulatory Surgery  
 Association  
 Annapolis, MD

**Director**  
 Digestive Health Education  
 Foundation  
 The Hepatitis Study Center  
 The Crohn's/Colitis Study Center

Outside Director, 3CPM Company, Inc.

**Member**  
 American College of  
 Gastroenterology  
 American Gastroenterological  
 Association  
 American Society for Gastrointestinal  
 Endoscopy  
 American College of Physicians  
 Baltimore County Medical Society  
 MED CHI State Medical Society

## Intervention

Endoscopic dilation using a TTS 20 mm pyloric dilator was performed. A total of three dilations were required to achieve sustained dilation of the pyloric sphincter.

## Post-Intervention EGG Results

Normalization of the EGG signal occurred following dilation. The 3 cpm signal returned to normal levels with normal response to water load.

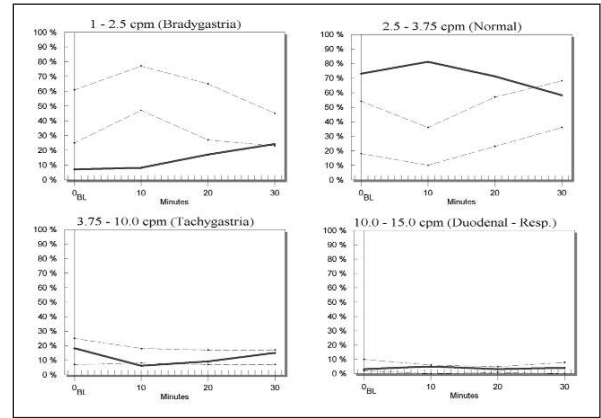
## Conclusion

Following dilation of the pyloric sphincter, the patient's symptoms disappeared. The results from the 3CPM Electrogastragram Analyzer quickly and easily aided in determining the cause of the patient's symptoms and helped in the selection of the best method to correct the underlying etiology.

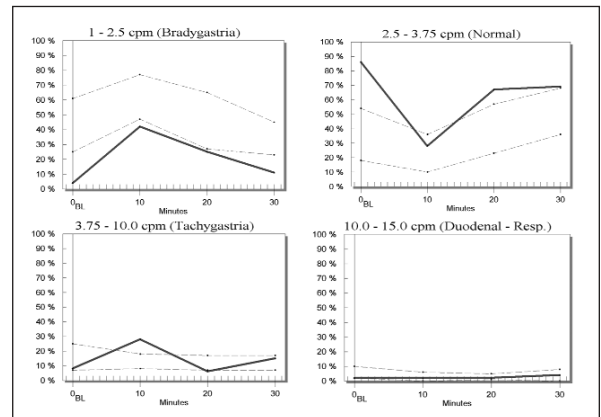
## References

1. Brzana RJ, Bingaman S, Koch KL. Gastric myoelectrical activity in patients with gastric outlet obstruction and idiopathic gastroparesis. *Am J Gastroenterology* 1998; 93: 1083-1089.

2. Hinder RA, Kelly KA. Human gastric pacesetter potential. Site of origin, spread and response to gastric transection and proximal gastric vagotomy. *Am J Surg* 1978;133:29-33.



(A) Pre-intervention



(B) Post-intervention

**Figure 2.** Resolution of EGG Pattern Post-intervention. Patient's patterns of movement in (B) now match those of control values. Abnormal amplitude and water load response in (A) are also resolved.



3CPM Company, Inc.  
7402 York Road  
Suite 100  
Towson, Maryland 21204  
United States of America

Web: [www.3CPMCompany.com](http://www.3CPMCompany.com)  
Email: [information@3CPMCompany.com](mailto:information@3CPMCompany.com)